



Western Michigan University
ScholarWorks at WMU

Honors Theses

Lee Honors College

Spring 2010

Stuck Together: Searching for a Model of Peritoneal Adhesions Using the August Rat

James W. Bathe

Western Michigan University, jbathe@med.wayne.edu

Follow this and additional works at: https://scholarworks.wmich.edu/honors_theses

 Part of the Surgery Commons, and the Tissues Commons

Recommended Citation

Bathe, James W., "Stuck Together: Searching for a Model of Peritoneal Adhesions Using the August Rat" (2010). *Honors Theses*. 129.

https://scholarworks.wmich.edu/honors_theses/129

This Honors Thesis-Open Access is brought to you for free and open access by the Lee Honors College at ScholarWorks at WMU. It has been accepted for inclusion in Honors Theses by an authorized administrator of ScholarWorks at WMU. For more information, please contact wmu-scholarworks@wmich.edu.



**Stuck Together: Searching for a Model
of Peritoneal Adhesions using the
August Rat**

James W. Bathe

Western Michigan University

Department of Biology

Table of Contents

Section 1: Review of Literature	3
Introduction.....	3
The Healing Process and Etiology of Adhesions.....	4
Current Prophylaxis of Adhesions.....	6
A Potential Solution.....	7
Creating a Model.....	8
Section 2: Materials and Methods	9
Procedure Overview.....	9
Animals.....	9
Anesthesia.....	10
Format of Surgeries.....	10
Phase I.....	10
Phase II.....	12
Histology.....	15
Section 3: Results and Discussion	16
Surgical Summary.....	16
Gross Pathological Findings.....	16
Histology.....	17
Discussion.....	18
Relevant Tables and Images.....	19
Section 4: Conclusion	24
Section 5: References	25

Potential Conflicts of Interest: Undergraduate Teaching Assistant for the Department of Biology at WMU; Emergency Medical Technician for Van Buren EMS which is owned by Bronson Healthcare Group.

Section 1

REVIEW OF LITERATURE

Introduction

Though the medical community has made vast advances in the field of abdominal surgery, one huge issue plagues these procedures. Fibrous adhesions, which are a by-product of the healing process [5,6], often appear post-surgically as a result of peritonitis related to the surgery [1,2]. These adhesions can be either primarily “scar tissue” or excess “healthy tissue” [5], and are the leading cause of intestinal obstruction in modern medicine [2,3]. Shockingly, adhesions occur in up to 96% of patients undergoing intra-abdominal surgery [5,6]. One study found that 5.7% of all readmissions for patients post-intra-abdominal-surgery were directly related to the adhesions [6]. Adhesions can lead to multiple complications other than small bowel obstructions such as inadvertent enterotomy (holes being cut in the intestine) at the time of adhesiolysis, chronic pain, and female infertility [3,5]. Additional complications arise from the adhesions preventing the free movement of organs and causing torsions or strangulations. These can lead to necrosis of vital organs putting the patient in peril and causing difficulty during subsequent surgical procedures [4].

The causes of the peritonitis, and therefore the adhesions, are traced back to three key sources: the trauma caused by surgery, irritants, and infection [2]. The most common preventative measures beyond aseptic surgery and techniques to limit trauma are the placement of various “barriers” to prevent adhesion formation [7,8]. However, many of these barrier methods still show adhesions being a common factor in their

usage [3,7,8]. As such, perhaps new surgical paradigms and new materials may be required to provide the best possible patient outcome.

The Healing Process and Etiology of Adhesions

A review of the healing process will provide better understanding of the formation of adhesions post-surgery. Following injury, the body reacts in a way to repair the damage while controlling the possibility for further damage. The complex process generally follows the following steps according to *Robbins and Cotran Pathologic Basis of Disease 7th edition*:

1. Inflammation
2. Proliferation and migration of parenchymal and connective tissue cells
3. Angiogenesis and granulation-tissue formation
4. Extra-cellular matrix formation
5. Tissue remodeling
6. Wound contraction
7. Acquisition of wound strength

Inflammation occurs directly after injury or infection and focuses on the removal of pathogens and dead tissues while isolating the site of injury. The movement of parenchymal and connective tissue cells to the site provides the building blocks for the future steps. Next, angiogenesis provides a pathway for additional resources to be sent to the site of injury. The newly formed blood vessels are leaky and allow direct access by the blood to provide pathways for new proteins and cells to arrive. The granulation-tissue cells work to direct this process and organize the other processes through

chemical signaling. Furthermore, macrophages show up to clear out the area of unneeded tissue and waste. These tissues work to form the new extra-cellular matrix (ECM) with which the new tissues will be intimately connected and utilize in almost all their functions. The tissue then is transformed from primarily granulation tissue to scar tissue by remodeling the ECM and tissue types at the wound site. Connective tissue in the area then contracts to shrink the wound back down and finally works to reinforce the tissue back to a working state.

Adhesions form between steps three and four of this process [9]. In these areas, the unfocused tissue formation can lead to otherwise healthy areas being attached to the wounds or even other nearby healthy tissue. When inflammation occurs, this tissue formation is drawn to the area due to chemical signaling and any tissue nearby experiencing ischemia (a common cause of inflammation) is at highest risk for forming adhesions [9, 10]. Though most of these attachments are dissolved (by tissue plasminogen activator (tPA) [12], some get fibrous support and remain, forming the adhesions in question [9]. The general idea of adhesion formation is shown in Figure 1.

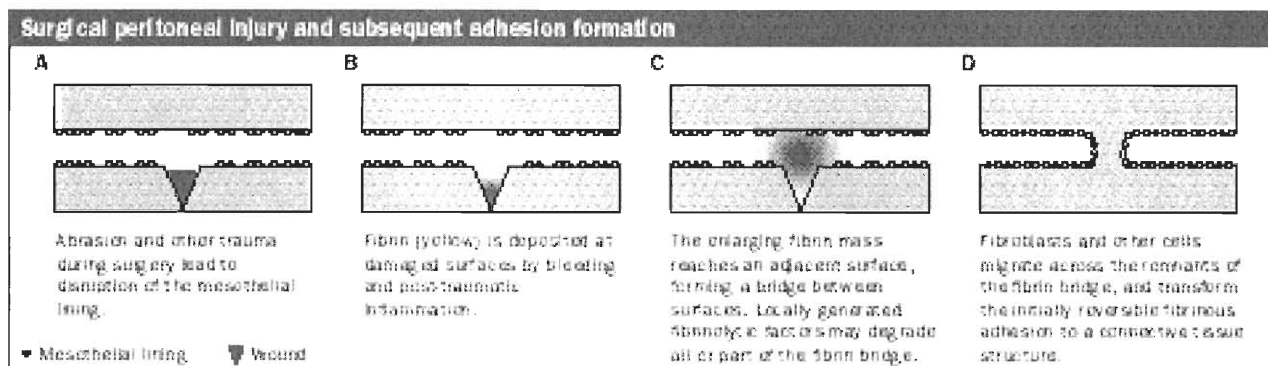


Figure 1. (From [12])

Current Prophylaxis of Adhesions

As the cause of inflammation (and therefore the adhesions) can be traced back to three specific areas (trauma due to surgical technique, foreign bodies, and infection), the medical establishment has been searching for solutions in these areas. To prevent trauma, laparoscopy has been preferred over the much more traumatic laparotomy [11]. With small holes, the amount of adhesions is greatly reduced. However, they are still produced [11,12].

Another prevention technique which has been discussed for some time has been not closing the peritoneum. Originally, closure of the peritoneum was accomplished to restore the surgical site to a state closer to anatomically normal [4]. However, more recent studies have revealed that at times, a 100% increase in adhesions occurred with closure of the peritoneum, more so in those closures that utilize catgut [13]. Currently there is a lot of debate about whether or not to close the peritoneum; a common thread seen in many studies holds that this is highly dependent on the type of surgery, location, and methods used [9,12,14].

Various other surgical techniques have been applied in the prevention of adhesions. Ergul and Korukluoglu discuss the various techniques in detail. For instance, due to the findings that ischemia leads to increase of adhesions involving the peritoneum, the authors suggest that using techniques of closure that minimize pressure such as mattress stitches are the best choice for closure. Hemostasis is also of utmost importance because clots possess all the triggers to encourage the healing process and thus, when they occur in the abdomen, trigger large numbers of peritoneal adhesions. The authors also discuss potential pharmacological prophylactics, though

none of the suggested techniques have been studied intensively at this time [13]. Finally, they discuss implantable physical barriers that have shown some promise though they vary in effectiveness.

A Potential Solution

Chitosan, the *N*-deacetylated derivative, has become something of interest the medical community as of late. Chitosan is produced very frequently from waste products from food, often crustaceans such as shrimp, and is used in a variety of industries, thus showing high availability and low cost [16]. It shows pro-immunological properties, bacteriostatic qualities, anticoagulant traits in some applications, and hemostatic properties in others [15]. However, most relevant to this thesis is the findings that chitosan may prevent adhesions from surgery that enters a body cavity. A few key studies illustrate the potential that chitosan has to become a new and vital part of abdominal surgery.

In a study by Kennedy et al., the researchers utilized *N,O*-carboxymethyl chitosan (NOCC) (chitosan that has been carboxymethylated) as an application in surgeries on rats that they would induce injury on. The proposed benefit of this would be that since NOCC is structurally similar to hyaluronic acid, a component in the extracellular matrix that has been found to promote wound healing, NOCC may provide rapid healing and prevention of healing complications by returning the tissue to a near non-damaged state as quick as possible. The authors performed a series of surgeries on Sprague Dawley rats, causing some damage to the uterus in one group and the cecum in the other. Then, they would sew the damage shut and then close. They

utilized NOCC when they first opened by coating the peritoneum with a 2% solution or 1% gel before incision, when they had repaired the damage the caused with the same solution or gel, and finally when they closed, they recoated the peritoneum just before the closure. Their results show significant reduction in number and size of peritoneal adhesions when compared to the non-treatment control and to the hyaluronic acid groups. The authors hypothesize that while NOCC promotes healing, it prevents deposition of fibrin which is the key part of the cascade to adhesion [18]. They later confirmed their findings and were able to find that NOCC application does not interfere with common surgical procedures' efficacies and works best when applied just after repair and again just before closure [17]. Various other studies confirm these findings [for example 19-22] and thus, NOCC (especially in gel preparations) seems to be a potentially significant treatment to be applied in nearly all abdominal surgeries.

Creating a Model

In order to proceed with further research on chitosan as an anti-adhesive treatment, we first must devise a model. This thesis is aimed at creating a model of adhesion that produces reliable amounts and severities of adhesions in rats. A previous study has found that blood and blood clots (common occurrences that arise from surgery) produce reliable adhesions in rats [23]. Another suggests that cecal defects along with peritoneal defects may be a reliable model [24].

Section 2

MATERIALS AND METHODS

Procedure Overview

After receiving institutional animal care and use committee approval, we arranged for 24 rats to be involved in the study. The animals used were August strain rats. The rats were originally divided into 3 equal groups of 8 animals, each group receiving one of three treatments but due to time constraints, the silk group was reduced to 2 subjects. The treatments varied if repair of damage would be performed and if vicryl or silk sutures would be used for repair. The animals would undergo surgery to create serosal injury on the antimesenteric border and a treatment would then be applied. The animals would then be closed and allowed to recover for 3 weeks. After three weeks, the animals would be sacrificed and gross pathology would be performed as we collect the cecum. After this, the site of injury and any remaining adhesions, if present, would undergo histology.

Animals

All animals utilized were adult August (AUG) rats. All animals were handled and housed in accordance with Institutional Animal Care and Use Committee (IACUC) guidelines at Western Michigan University (IACUC numbers:). Food and water provided *ad libitum* pre- and postoperatively. The colonies were maintained under a 12hr/12hr-light/dark cycle at 21-28°C with rodent chow #5001 (Purina Mills, St. Louis, MO) and water was reverse osmosis purified.

Anesthesia

We only performed surgeries on one animal at a time and as such, the general anesthesia was applied to only one animal at a time. Animals were anesthetized using (%) isoflurane (Fluothane) at 2.0-2.5 (units) with oxygen flowing at 2 liters per minute using (device). Animals were first secured in an airtight container (MFG and Location) with the anesthesia flowing through from one end to an open tube leading to the inside of a fume hood. When the animal went unconscious and was unresponsive to sound stimuli, the animal was moved to the prep area and, subsequently, to the surgery area while using a nose cone (MFG and Location) (with the same concentration and flow from the aforementioned machine) which was secured to the animal using 3M Transpore tape (St. Paul, MN). Anesthesia was maintained throughout the surgical procedure and was stopped when the animal was closed.

Format of Surgeries

-Phase I: Injury-

-Surgical Preparation-

After being rendered unconscious, animals were moved to a prep area that was covered with a disposable absorbent pad overlay while maintaining anesthesia as above. The animal had its abdomen shaved using hair clippers (MFG and Location) and duct tape (MFG and Location) to remove excess hair in an approximately 3cm by 3cm area. Then the animal was moved to the surgical area (still under anesthesia) which had a heating pad (MFG and information) to maintain body heat which was covered with another disposable absorbent pad overlay. Here, the animal had the surgical site

washed with 70% isopropyl alcohol three times to ensure a clean field and reduce postoperative infections.

-General Surgical Procedure-

Surgeons utilized aseptic technique at all times, including wearing of surgical gloves and masks and attempting to maintain an aseptic field. Surgeons then utilized a #15 blade disposable scalpel and two serrated forceps to perform a midline celiotomy that was approximately 2cm in length. Then, the cecum was eviscerated using either digital manipulation or with smooth tip forceps. Once eviscerated, the cecum was gently laid upon the “Adheserator”, a template made of flexible clear plastic with an opening in the top measuring 1.5 x 1 cm. We maintained moisture on the cecum and “Adheserator” using normal saline solution (MFG location) applied with a sterile 3x3 gauze pad. The “Adheserator” was held in place by manual pressure which caused some cecal tissue from the anti-mesenteric region to push through the opening. This tissue was then abraded using a *Trim* 5 inch Sapphire file (W.E. Bassett Co., Sheldon, CT) with fifteen gentle strokes (enough to cause punctate bleeding). Then a sterile 3x3 gauze pad was held with direct pressure on the site to prevent excessive hemorrhage. Once hemostasis was achieved, we moved on to the experimental part. To close, the cecum was gently replaced into the peritoneum with care to prevent kinking of any internal organs using smooth tip pickups and digital manipulation. The animal was then closed in an interrupted fashion using *Ethicon* 4-0 suture (Somerville, NJ) using a standard needle driver and serrated tip forceps. The closed incision was then cleaned with 3x3 gauze pad soaked with normal saline solution and was marked with (name), a blue dye (MFG and Loc), as to monitor for the animals tampering with the closure. The animals

then had the nosecone removed and all anesthesia stopped. Then, they were moved to clean, single housing cages and allowed to recover. After recovery, they were returned to housing in the Western Michigan University facility that they were previously residing in.

-Experimental Groups-

1. In this group, the serosal injury was repaired using *Ethicon* 5-0 Vicryl suture (Somerville, NJ) using Lembert sutures.
2. In this group, the serosal injury was repaired using *Ethicon* 5-0 Silk suture (Somerville, NJ) using Lembert sutures.
3. In this group, the serosal injury would not be repaired and the animal was closed as above.

-Post Operation-

The animals were observed every 6-8 hours for the first 48 hour period and then daily for signs of infection or other symptoms of complication such as pain responses, peritonitis, or intestinal obstruction. Food and water were provided *ad libitum* (as it was pre-operatively).

-Phase II: Tissue Harvest-

On day 21, post operation, we euthanized the animals using carbon dioxide gas inhalation. To ensure the animals were dead, toe and tail pinches were performed to test for any reflex or tone. The animals were then placed in an identical surgical set up as above, minus the anesthesia equipment. This time, serrated tip pick ups, surgical scissors, and a #15 blade disposable scalpel were used to create a “U” shaped incision where the bend of the “U” would be oriented cranially and the open end would be

oriented caudally. The incision was performed on the abdominal area as to frame around the original surgical incision from Phase I. As they were performing the incision, the surgeons would observe into the incision to make sure as to not disturb any adhesions clinging to the parietal peritoneum. When the incision was completed, the “flap” of tissue was folded back and inspected for any adhesions clinging to it or the Phase I incision. After this, the entire abdominal cavity was searched and examined for adhesions. Finally, the cecum itself was focused on and the site of injury was examined for adhesions. Additionally, the surgeons examined the peritoneal cavity for any abscesses, infections, or obstructions.

-Adhesion Classification-

Adhesions were classified by location, structures involved, and density. Density was graded as follows:

Mild adhesions: filmy adhesions easily broken by digital manipulation.

Moderate adhesions: adhesions of such density that gentle manipulation causes either tearing of the serosa, or sharp scissor dissection is required to divide the adherent tissue.

Dense adhesions: adhesions that are difficult to divide by sharp scissor dissection, resulting in further serosal or muscularis injury or bowel perforation.

Obstructing adhesions: adhesions that cause proximal bowel dilatation and distal decompression across which small bowel contents or air cannot be moved.

-Tissue Harvest-

After examination and adhesion classification was completed, the surgeons then utilized sharp surgical scissors to remove the cecum and any attached adhesions. This tissue was then placed in a specimen cup (MFG and Loc) which was full of cold 10% formalin (MFG/Source and Loc) for 15 to 30 minutes. After this, the formalin was drained off and replaced with fresh, cold 10% formalin. The tissue was placed in cold storage at approximately 4.4°C overnight. Afterwards, the tissue was placed in cold 95% ethanol until it could be analyzed.

-Disposal of Animals-

After necropsy, the corpses were moved to a storage freezer in the animal facility and disposed of by the University Health and Safety Department.

Histology

Samples for histology were taken using cross sections of cecum at the injury site in order to look for relevant changes such as chronic inflammation throughout the entire cecal wall. Additional samples were taken as squares of tissue from the injury site and any remaining attached adhesions were evaluated as well. Sites of chronic inflammation such as many eosinophils and new collagen formation were assessed and photographed. As many of the adhesions were destroyed in the removal process, most histological data focuses on relevant changes at site of injury and repair. All histological evaluations were performed by Dr. Charles MacKenzie from Michigan State University.

Section 3

RESULTS AND DISCUSSION

Surgical Summary

The summation of surgical procedures as performed is found in table 1. Though efforts were made to maintain a standard procedure across all subjects, complicating factors such as hemorrhage occurred and are noted. Specimens were labeled “XWM##” where X was replaced with N for non-repair, V for vicryl repair, and S for silk repair; WM represented Western Michigan; and ## represented the overall number of the specimen and order of surgery.

Gross Pathological Findings

The whole set of pathological results can be found in table 2.

-Non-Repair-

These specimens (NWM07, NWM08, NWM10, NWM11, NWM12, NWM13, NWM14, and NWM15) had a mean adhesion grade of 0.87. NWM07 was not defecating post op and at day 8, it was decided to euthanize the subject to prevent suffering. When adhesions were found, they were often singular and moderate. Overall, the adhesions found were neither numerous nor extensive.

-Vicryl Repair-

These specimens (VWM01, VWM02, VWM03, VWM04, VWM09, VWM16, VWM17, and VWM18) had a mean adhesion grade of 2.125. The only unusual subject in this group was VWM09 who needed an additional suture to control bleeding post

injury. All specimens had adhesions present and they were found to be consistently moderately adhered with moderate numbers of adhesions. VWM09 experienced more extensive adhesions, though this is likely due to the extra trauma of the hemorrhage that was controlled via suture.

-Silk Repair-

These two specimens, SWM05 and SWM06, had grades of 4 and 3 respectively, with a mean adhesion grade of 3.5. Adhesions were moderate to dense and were found to be numerous.

Histological Findings

The histology of the sites of damage (and repair, if applicable) was investigated. However, while significant histological examples of chronic inflammation were always associated with adhesions, adhesions were not always associated with chronic inflammation. Current experimental design focused primarily on gross pathological findings as these findings would be more useful for surgeons performing abdominal surgeries. The histological findings were interesting, but not a significant source of information for this study.

Images 2 and 3 show a site of chronic inflammation around a remaining suture in the wall of the cecum from one of the subjects and image 4 shows a normal cecal wall. These are examples of what we were searching for during our histological studies. Again, while interesting, in this study design, these findings are unfortunately not able to tell us much.

Discussion

Out of the three treatment arms, silk appears to produce the most severe and extensive adhesions. However, due to time constraints, we were not able to complete the entire silk group. The vicryl group also produces adhesions but smaller in number and lower in severity. The non-repair group produced few adhesions and suggests that during abdominal surgery, efforts should be made to avoid unnecessary repairs as these repairs appear to induce additional adhesions to form at the sites of repair. From the data we collected, it would appear that creating the damage with the nail file, repairing with 5-0 vicryl sutures, and then closing produces the most reliable method for obtaining adhesions for study. Additionally, as the histology shows, it was found that foreign bodies such as hair produce adhesions as well. For experimentally sound results, efforts should be made to reduce or eliminate any unplanned foreign bodies in the surgical site as they are unnecessary and potentially confounding to data obtained from the affected specimens.

Relevant Tables and Images

<u>Subject</u>	<u>Sex</u>	<u>Strokes for Injury</u>	<u>Method of Repair</u>	<u>Surgical Notes</u>
VWM01	Male	10	3 5-0 Vicryl Sutures	Closed Per Protocol
VWM02	Female	15	4 5-0 Vicryl Sutures	Closed Per Protocol
VWM03	Male	15	4 5-0 Vicryl Sutures	Closed Per Protocol
VWM04	Female	15	3 5-0 Vicryl Sutures	Closed Per Protocol
SWM05	Male	18	3 5-0 Silk Sutures	Closed Per Protocol
SWM06	Female	18	3 5-0 Silk Sutures	Closed Per Protocol
NWM07	Male	18	No Repair	Closed Per Protocol. Subject euthanized due to lack of defecation at day 8 post op.
NWM08	Female	23	No Repair	Closed Per Protocol
VWM09	Female	15	2 5-0 Vicryl Sutures and 1 additional Vicryl Suture for bleeding control	Closed Per Protocol
NWM10	Male	15	No Repair	Closed Per Protocol
NWM11	Female	15	No Repair	Bleeding was controlled with direct pressure with 3x3 guaze pad. Closed Per Protocol
NWM12	Male	15	No Repair	Closed Per Protocol
NWM13	Female	15	No Repair	Bleeding was controlled with direct pressure with 3x3 guaze pad. Closed Per Protocol
NWM14	Male	15	No Repair	Bleeding was controlled with direct pressure with 3x3 guaze pad. Closed Per Protocol
NWM15	Female	22	No Repair	Closed Per Protocol
VWM16	Male	15	4 5-0 Vicryl Sutures	Closed Per Protocol
VWM17	Female	15	4 5-0 Vicryl Sutures	Closed Per Protocol
VWM18	Male	20	4 5-0 Vicryl Sutures	Closed Per Protocol

Table 1. Surgical Procedure Summary

Subject	Gross Pathology	Adhesion Grade
VWM01	Moderate adhesion to midline incision, 2 mild adhesions from pelvis to cecum, 1 mild adhesion on the cecum	Grade 2
VWM02	One mild adhesion to the repair site on the cecum	Grade 1
VWM03	Suture found outside of healed incision (incidental). One mild adhesion to repair site on cecum. One dense adhesion of small bowel to cecum. One mild and one moderate adhesion adjacent to the repair site.	Grade 3
VWM04	One moderate adhesion to the repair site on the cecum	Grade 2
SWM05	Several (3) moderate adhesions to suture site, with an additional adhesion of cecum to small bowel. Moderate pelvic adhesion to cecum away from the repair site. Dense adhesion of cecum to cecum away from injury site.	Grade 4
SWM06	Two moderate adhesions to abdominal wall. Moderate adhesion away from the repair site on cecum and 2 moderate adhesions to repair site.	Grade 3
NWM07	Petechial bleeding and a hematoma on site of injury. Entire bowel and cecum were flaccid and without adhesion formation. No distended bowel identified.	Grade 0
NWM08	Moderate adhesion to cecum. Incidental: 3x3 cm. mass in lower right extremity appearing to be solid, fleshy tissue.	Grade 2
VWM09	Moderate adhesion on cecal border. Large bowel adhered densely to cecum (approx. 2.5 cm.)	Grade 4
NWM10	Mild adhesion to incision line, underside of abdominal wall.	Grade 1
NWM11	Moderate adhesion to cecum.	Grade 2
NWM12	Moderate adhesion to abdominal wall at incision site	Grade 2
NWM13	No adhesions	Grade 0
NWM14	No adhesions	Grade 0
NWM15	No adhesions	Grade 0
VWM16	Mild adhesion to anterior cecum	Grade 1
VWM17	Moderate adhesion to anterior cecum	Grade 2
VWM18	One moderate adhesion omentum to anterior cecum. One moderate adhesion adnexa to pelvic sutures	Grade 2

Table 2. Necropsy Results. Adhesion Grading system explained in table 3.

Grade	Criteria
0	No adhesions
1	One or two mild adhesions
2	Many mild adhesions, one or two moderate adhesions, or a combination of mild and moderate adhesions
3	Many moderate adhesions, one or two dense adhesions, or a combination of mild, moderate, and dense adhesions
4	Many dense adhesions or a large combination of mild, moderate, and dense adhesions
5	So many adhesions that surgery becomes difficult and counting individual adhesions is almost impossible

Table 3. Adhesion Grading criteria for gross pathology

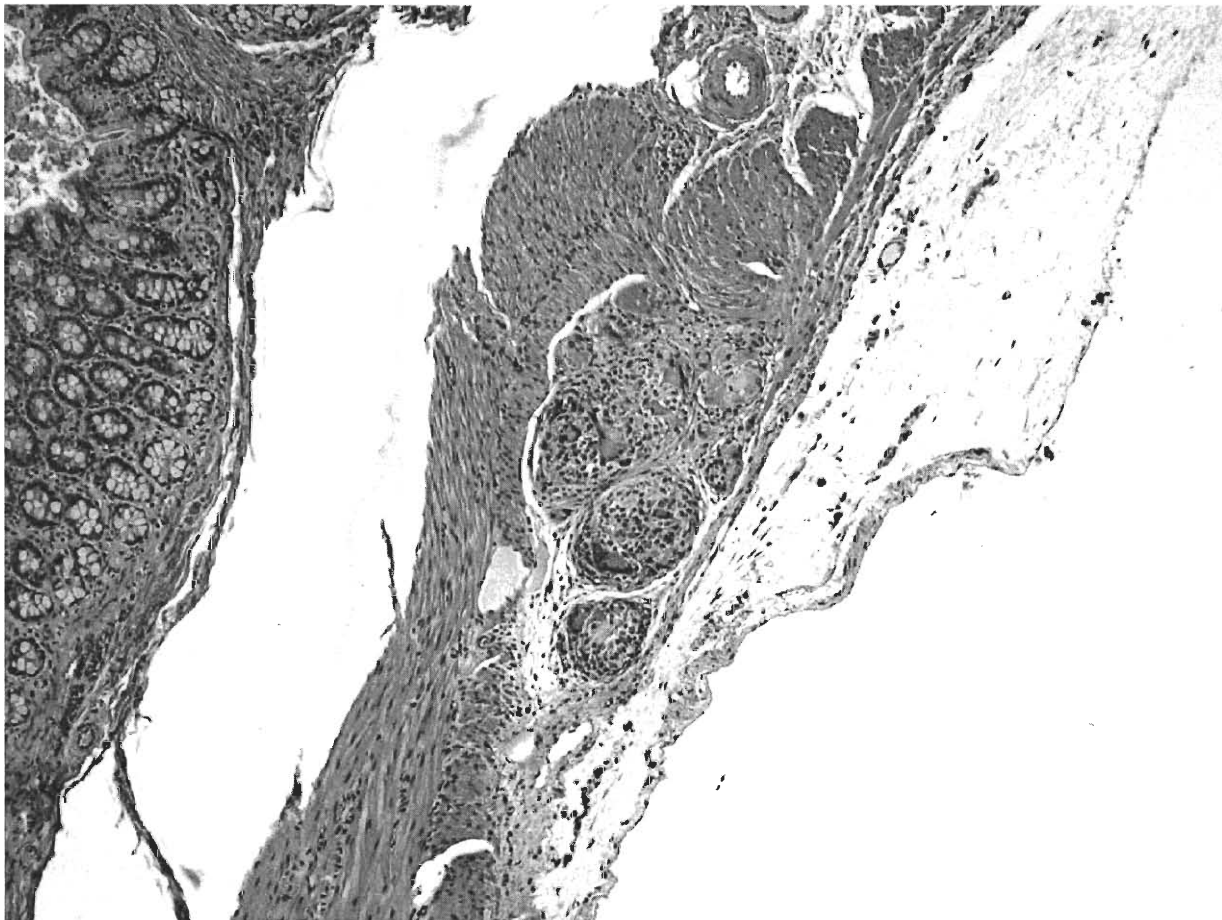


Figure 2. (40x Biological Imaging Center, WMU) Chronic inflammatory response surrounding a suture in the cecal serosa from specimen VWM9. Classical chronic inflammatory response.

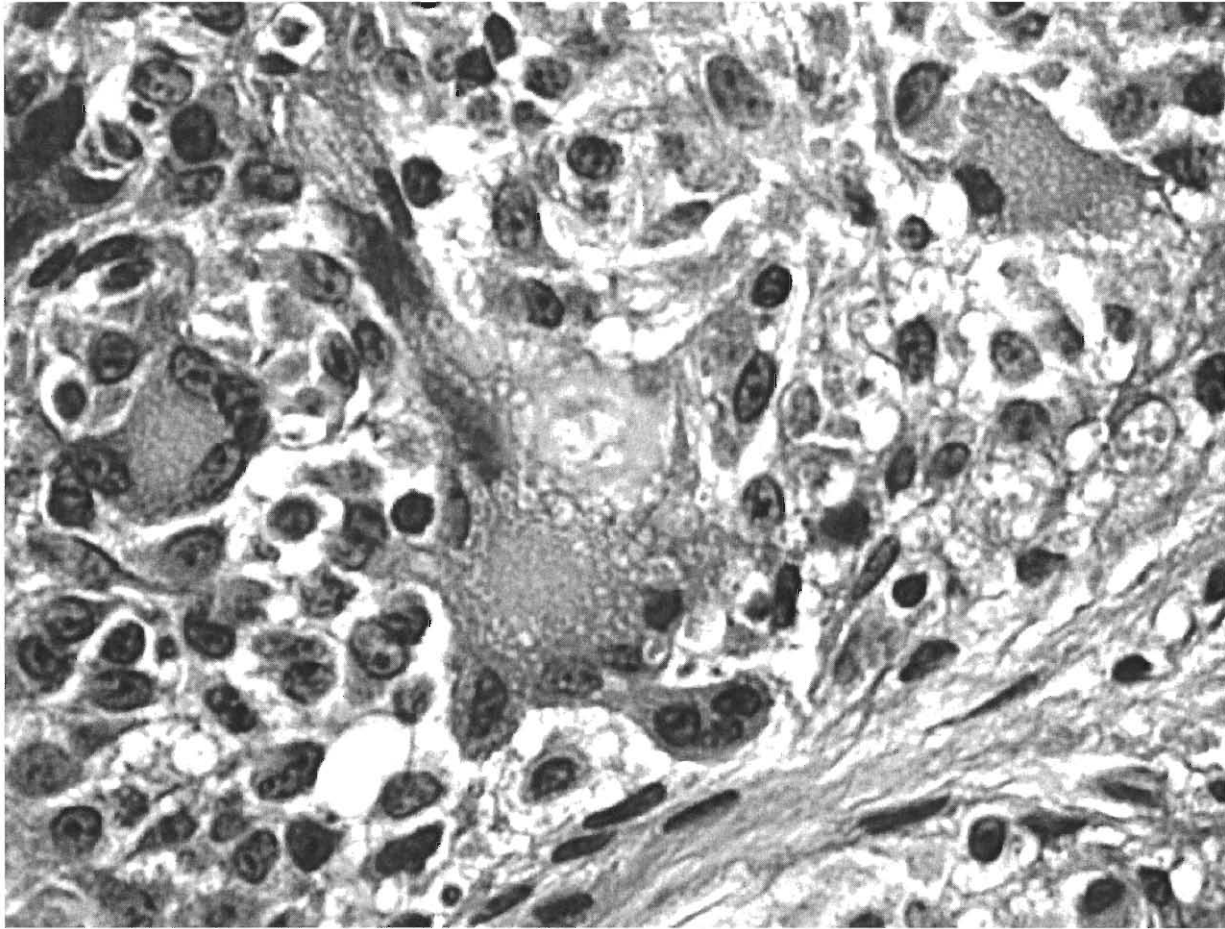


Figure 3. (400x. Biological Imaging Center, WMU) Close up of remaining suture (gray area in center of image) surrounded by giant cell and eosinophils from VWM09.

Classical chronic inflammatory response.

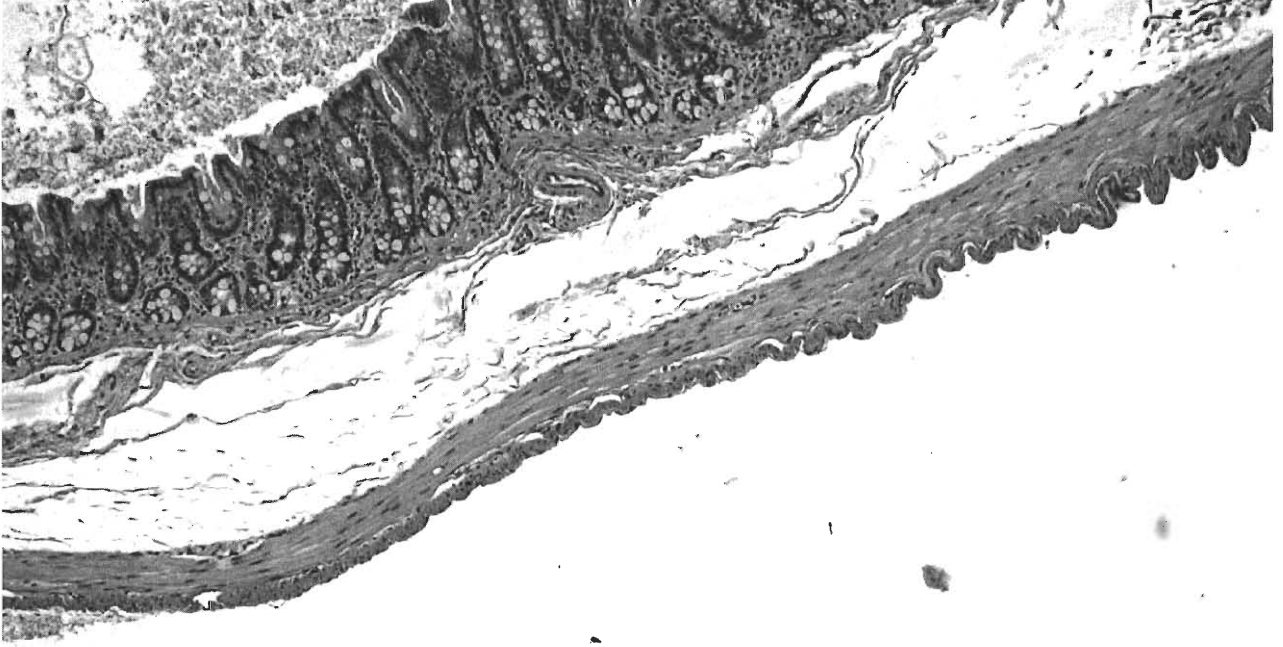


Figure 4. (40x Biological Imaging Center, WMU) Normative serosal wall from VWM09.

Section 4

CONCLUSION

People come to the medical community in search of help with the complex problems that their bodies may be undergoing. However, in order to truly meet the demands of this important duty, efforts must be made to prevent further harm from befalling the patient. Abdominal surgery is a common occurrence today and, unfortunately, so are adhesions post-op. As such, it is common practice to prepare for the almost certain eventuality of them occurring. With the work we have done here, there may be a chance to find new ways of looking at abdominal surgery and new treatments to prevent adhesions. Further work is needed to confirm these results and also to investigate the role chitosan might play in prevention of adhesions. However, I feel as though we are on the brink of completely changing the way we think about abdominal surgeries. With a little push, we can break free from the bonds that adhesions have placed on medicine.

Section 5

WORKS CITED

- [1] Abbas, A.K., Fausto, N., Kumar, V. *Robbins and Cotran Pathologic Basis of Disease*, 7/E Philadelphia: Elsevier Saunders, 2005: 856.
- [2] Coakley, J.B., Daniel, P.O. "The influence of suturing and sepsis on the development of postoperative peritoneal adhesions." *Annals of the Royal College of Surgeons of England* 74 (1992): 134-137.
- [3] Jin, J. et al, "Human Peritoneal Membrane Controls Adhesion Formation and Host Tissue Response Following Intra-Abdominal Placement in a Porcine Model." *Journal of Surgical Research* 156 (2009): 297-304.
- [4] Cheong, Y.C. et al, "To close or not to close? A systematic review and a meta-analysis of peritoneal non-closure and adhesion formation after caesarean section" *European Journal of Obstetrics & Gynecology and Reproductive Biology* 147 (2009): 3-8.
- [5] Binnebösel, M. et al, "Morphology, quality, and composition in mature human peritoneal adhesions." *Langenbecks Arch Surg* 393 (2008): 59–66.
- [6] Ellis, H. et al. "Adhesion-related hospital readmissions after abdominal and pelvic surgery: a retrospective cohort study." *The Lancet* 353 (1999): 1476–80.

- [7] Voskerician, G. et al. "Human Peritoneal Membrane Reduces the Formation of Intra-Abdominal Adhesions in Ventral Hernia Repair: Experimental Study in a Chronic Hernia Rat Model." *Journal of Surgical Research* 157 (2009): 108–114.
- [8] Matthews, B. et al. "Assessment of Adhesion Formation to Intra-Abdominal Polypropylene Mesh and Polytetrafluoroethylene Mesh." *Journal of Surgical Research* 114 (2003): 126-132.
- [9] Ergul, E. and Korukluoglu, B. "Peritoneal adhesions: Facing the enemy." *International Journal of Surgery* 6 (2008): 253-260.
- [10] Ellis H. "The aetiology of post-operative abdominal adhesions: an experimental study." *Br J Surg* 50 (1962):10.
- [11] Harris, D. A. and Topley, N. "Peritoneal adhesions." *British Journal of Surgery* 95.3 (2008): 271-272.
- [12] Holmdahl, L. "Making and Covering of Surgical Footprints." *The Lancet* 353 (1999): 1476-77.

- [13] Hubbard, T.B. et al. "The pathology of peritoneal repair: its relation to the formation of adhesions." *Annals of surgery* 165.6 (1967): 908.
- [14] Garrard, C.L. et al. "Adhesion formation is reduced after laproscopic surgery." *Surgical Endoscopy* 13.1 (1999): 10-13.
- [15] Ravi Kumar, M.N.V. "A review of chitin and chitosan applications." *Reactive and Functional Polymers* 46.1 (2000): 1-27.
- [16] Illum, L. "Chitosan and Its Use as a Pharmaceutical Excipient." *Pharmaceutical Research* 15.9 (1998): 1326-1331.
- [17] Costain, D.J. et al. "Prevention of postsurgical adhesions with N,O-carboxymethyl chitosan: Examination of the most efficacious preparation and the effect of N,O-carboxymethyl chitosan on postsurgical healing." *Surgery* 121.3 (1997): 314-319.
- [18] Kennedy, R. et al. "Prevention of experimental postoperative peritoneal adhesions by N,O-carboxymethyl chitosan." *Surgery* 120.5 (1996): 866-870.
- [19] Zhou, J. et al. "Reduction in postoperative adhesion formation and re-formation after an abdominal operation with the use of N, O – carboxymethyl chitosan." *Surgery* 135.3 (2004): 207-212.

- [20] Vlahos, A. et al. "Effect of a composite membrane of chitosan and poloxamer gel on postoperative adhesive interactions." *The American Surgeon* 67.1 (2001): 15-21.
- [21] Krause, T. et al. "Prevention of Pericardial Adhesions with N-O Carboxymethylchitosan in the Rabbit Model." *Journal of Investigative Surgery* 14 (2001): 93-97.
- [22] Zhang, Z., Zhou, X., Xu, Si. "Preventive effects of chitosan on peritoneal adhesion in rats." *World Journal of Gastroenterology* 12.28 (2006): 4572-4577.
- [23] Ryan, G. B., Grobéty, J., Majno G. "Postoperative Peritoneal Adhesions, a Study of the Mechanisms." *The American Journal of Pathology* 65.1 (1971): 117-149
- [24] Harris, E.S., Morgan, R.F., Rodeheaver, G.T. "Analysis of the kinetics of peritoneal adhesion formation in the rat and evaluation of potential antiadhesive agents." *Surgery* 117.6 (1995): 663-670